

Equine WELLNESS

Your natural resource!

SPECIAL ISSUE:

performance **HORSES**



TAME THE CLIPPING
Monster
Teach your horse how to clip

Equine
Thermography
Coloring the world of equine lameness

HOME
Sweet HOME
Our top 8 tips for selecting a boarding barn

KEEP YOUR *Cool*
Manage your horse's hydration this season

What's behind
Shockwave
therapy

Wow FACTOR!
Get that show ring shine - naturally

More Than
Metal
Shoeing options for transitioning horses

Display until August 14, 2012

\$5.95 USA/Canada



VOLUME 7 ISSUE 3



COLORING THE WORLD OF LAMENESS

EQUINE THERMOGRAPHY IS
GAINING ATTENTION FROM EQUINE
PROFESSIONALS AND RIDERS ALIKE –
COULD IT HELP YOUR HORSE?

BY JOANNA ROBSON, DVM, CVSMT, CMP, CVA, CSFT, CIT

It's nine in the morning and I pull my FLIR T400 thermal imaging camera out of its case and switch it on to warm up and calibrate. My patient, a young Warmblood gelding with an acute right hind limb lameness, is appropriately prepared and ready for his imaging. The conditions are perfect: warm but not hot, no wind, we're in a protected barn, and Vic is clean and dry. As I move carefully around my patient, setting up my shots, I'm suddenly drawing a crowd of onlookers – not unusual when the camera comes out. Comments like “Oh! That's so cool! What is that?” or “Is that the camera that sees the hot spots?” or “What's the red area mean?” echo through the barn aisle.

WHAT'S OLD IS NEW AGAIN

Most people think thermography is a new diagnostic tool for horses, but thermal imaging was introduced to the equine industry in the 1970s, primarily as a screening tool for racetracks and performance horses. However, due to expensive and rudimentary cameras, little knowledge of correct imaging techniques, and a lack of understanding about how to correctly interpret the images, the technology soon fell out of favor both with veterinarians and human medical professionals.

Nowadays, the use of thermography is steadily growing again in human screening for cancer, work-related injuries, and other physiologic processes, and its use is also increasing in the equine industry. So what has changed?

A DEMAND FOR NON-INVASIVE ALTERNATIVES

The equine industry has undergone a major transformation over the past three decades. Now a multi-billion dollar industry with huge financial stakes, there is a great demand for the latest and greatest in diagnostic equipment. There is also more emphasis on alternative medicine and non-invasive modalities. Riders and

trainers are well educated, and many expect the same quality of care for their animals that they would for their human family members.

“At the 1996 Olympic Games in Atlanta, where there was millions of dollars worth of equipment available to the equestrian teams, the most-requested diagnostic tool was thermography. It was fast. It was portable. It was non-invasive. It could detect injury sites before they became lameness problems, and could guide practitioners to specific anatomic areas for study using other diagnostic techniques. And it was extremely accurate when used by an experienced practitioner.”¹ The demand for thermal imaging has boomed with the industry's economic surge and with the desire for rapid, safe, non-invasive diagnostic tools.

ANATOMIC VS. PHYSIOLOGIC

The major difference between thermal imagery and traditional diagnostic modalities such as ultrasound is that one is *physiologic* while the other is *anatomic*.

- An anatomic diagnostic modality will show a specific lesion or problem in an anatomic structure at a static moment in time (e.g., a radiograph will show a bone spur in a hock).
- A physiologic modality such as thermal imaging cannot show a specific anatomic lesion, but does show a physiologic change in blood flow that helps localize a lesion and more easily shows changes over time (e.g., showing whether the bone spur in the hock is causing inflammation).

See the chart on page 42 for a comparison of the typical diagnostic tools available to horse owners. Based on this table, we can see that thermal imaging stands out as one of only two whole body imaging modalities, and is by far the most cost effective whole body imaging technology available.

PREVENTATIVE MAINTENANCE

Thermography is non-invasive, and is also the most effective “preventative” modality due to its ability to detect temperature changes indicative of early inflammation or circulatory disruption. Though the images are not able to tell the interpreter the specific nature of the lesion, the sensitivity of the camera for detecting temperature changes related to disease is key to its success. Changes greater than 1°F to 2°F are considered significant. In fact, thermal imaging has repeatedly revealed signs of soft tissue injury, such as tendon or ligament damage, up to two weeks *before* any clinical signs of lameness, heat or swelling were detected. Thermal imaging should be considered as much a diagnostic tool as a preventative maintenance tool. Also, equine insurance companies will often cover thermographic imaging, which makes it more accessible to horse owners.

While thermography shows great success in many applications (see sidebar) it is important to recognize it as another tool in the box and not a be-all-end-all diagnostic device. The camera detects surface heat, so deeper, smaller lesions may be missed, or chronic changes not currently affecting circulatory patterns may go undetected. But correct patient preparation and environment can maximize the potential outcome of a scan. So what are the most important factors for success with equine thermal imaging?

A SUCCESSFUL IMAGING SESSION

Standardization and correct patient preparation are *imperative* to minimize artifacts and maximize gain through blood flow and residual inflammation (or lack thereof). Artifacts such as moisture and sweat, dirt, caustic substances, bandages and blankets, can and will immediately destroy the correct interpretation of a scan. Long haircoats, feather (draft horses and Friesians), and unbraided manes or tails may interfere with imaging.

Environmental control cannot be over-emphasized as critical to a successful scan. Sunlight, radiant heat from metal roofs or barn siding, fans and breezes, and flooring in the barn (mats, dirt, concrete, etc.) can significantly alter a scan.

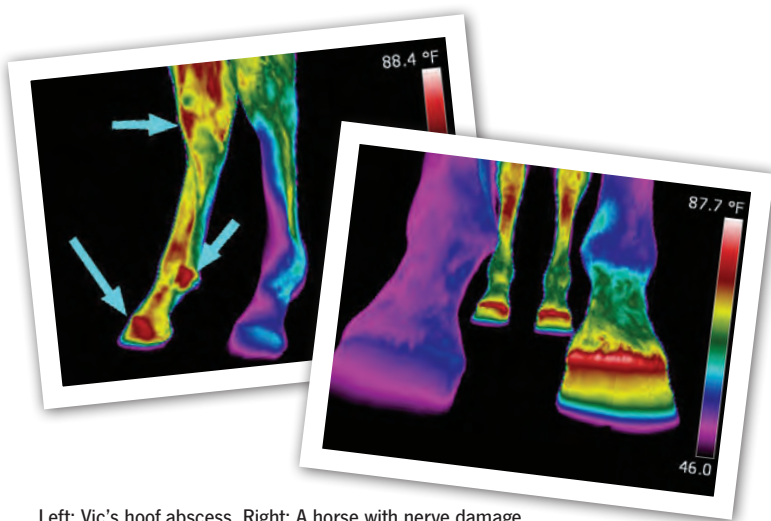
Having a clean dry patient in an environment free of drafts, direct sunlight or moisture, are keys to the success of your imaging scan, and to the repeatability and reliability that thermal imaging requires for continued acceptance in the veterinary and equine industries. Interpretation of the images is the other half of a successful imaging equation.

IT'S ALL IN THE INTERPRETATION


In keeping with veterinary practice laws, thermal imaging interpretation *must be done by a licensed veterinarian* –preferably one who is certified and/or experienced with thermography. Just

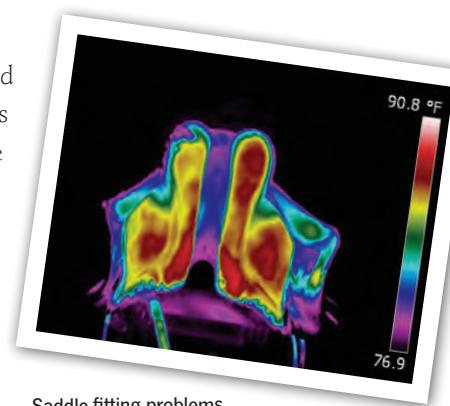
COMPARING DIAGNOSTIC TOOLS

MODALITY	DETECTION	COST	ADVANTAGE	DISADVANTAGE
MRI	Soft tissue and bone	\$1,200-\$3,000	Specific, anatomic	Expensive, requires anesthesia
CT	Soft tissue and bone	\$1,200-\$3,000	Specific, anatomic	Expensive, requires anesthesia
Nuclear scintigraphy	Bone and some soft tissue structures	\$500-\$2,000	Whole body, sensitive, physiologic	Not specific, will require follow-up diagnostics; usually three days in hospital, invasive
Ultrasound	Soft tissue, some bone	\$100-\$300 per region	Specific, anatomic	Limited by region, may require sedation and clipping
Radiographs	Bone, some soft tissue (if swollen or affected)	\$100-\$300 per image or region	Less expensive, good quality now with digital radiographs	Limited by region, may require sedation, radiation exposure
Thermography	Bone and soft tissue	\$200-\$400 for total body scan, often includes veterinary interpretation	Full body evaluation, non-invasive, early detection of problems before clinical signs, physiologic	Correct preparation is necessary for a good evaluation, artifacts may alter images, typically requires follow-up diagnostics
Veterinarian's lameness evaluation	General	\$150 plus regional blocks	Considered the standard “first step”, important general baseline	Often requires follow-up diagnostics, not always sensitive or specific



Left: Vic's hoof abscess. Right: A horse with nerve damage.

and ultrasound, which could show specific lesions; and was therefore discarded because of its lack of specificity. Now, with significantly better technology, and recognition of the importance of standardization, thermal imaging is taking its rightful place in equine diagnostics. 



Saddle-fitting problems.

1. Brown, K. Thermography: Diagnosis tool for horses. *The Horse*, Oct 2001, 490

as a radiology technician's job is to take excellent pictures, the thermographer must also take excellent thermal images, but neither should be making diagnostic calls unless they are also the veterinarian. Ask where your technician was certified, if he/she has a standardized patient preparation and imaging series, and if he/she has a veterinarian experienced in thermal imaging to interpret the images. To learn more about becoming a certified equine thermographer or to find a technician in your area, please visit equineir.com or ieinfrared.com.

IN KEEPING WITH VETERINARY PRACTICE LAWS, THERMAL IMAGING INTERPRETATION MUST BE DONE BY A LICENSED VETERINARIAN – PREFERABLY ONE WHO IS CERTIFIED AND/OR EXPERIENCED WITH THERMOGRAPHY.

AND WHAT ABOUT VIC?

Vic's images showed an asymmetry in the hind limbs. There was increased blood flow throughout the right hind leg. Possibilities for the cause included a muscle strain, joint injuries, hoof infection, or tendon-ligament injury, but based on his complete history a hoof abscess was suspected. The veterinarian and farrier evaluated his foot carefully and found a deep pocket of infection. The owner was pleased to avoid flexions and nerve blocks, radiographs, and an expensive work-up. While not every case is as straightforward, Vic's case is a good example of lameness localization and a successful outcome using this whole horse non-invasive tool.

Standardization and correct interpretation are crucial to the continued acceptance of thermal imaging as a diagnostic modality. Thermal imaging failed during its inception in the equine industry because of a lack of standardization and understanding of the technology and its correct use. Thermal imaging was compared to radiographs

APPLICATIONS FOR THERMOGRAPHY

Some specific applications in the equine industry include:

- Whole horse baseline scans – may prevent problems through early detection
- Pre-purchase evaluations – whole horse scans often find otherwise missed problems
- Saddle-fitting evaluation – pressure, balance, uneven flocking, bridging, rider imbalance
- Back health – kissing spine, muscle inflammation, saddle-fit problems
- Farriery and hoof health – abscess, bruising, laminitis, imbalanced trimming/shoeing/loading
- Lameness localization – detection of changes in circulation or nervous system function
- Monitoring healing of soft tissue over time – easy serial imaging of tendons, ligaments, muscles
- Pre-race or pre-competition screening – preventing breakdowns or catastrophic injuries
- Ethics in sport – anti-soring of gaited horses, anti-rapping
- Research and development – footing surfaces, mats and pads, therapeutic equipment

JOANNA ROBSON, DVM, CVMSMT, CMP, CVA, CSFT, CIT IS THE OWNER OF INSPIRITUS EQUINE, INC. (INSPIRITUSEQUINE.COM) IN NAPA, CALIFORNIA, AND A CO-FOUNDING MEMBER OF HIPPOH FOUNDATION (HORSE INDUSTRY PROFESSIONALS PROTECTING OUR HORSES). HER PRACTICE IS DEDICATED TO A WHOLE HORSE APPROACH COMBINING ACUPUNCTURE, CHIROPRACTIC, THERMOGRAPHY, AND SADDLE-FITTING WITH LIKE-MINDED INDUSTRY PROFESSIONALS FOR THE BEST HEALING APPROACH FOR THE PATIENT. SHE IS A NATIONAL AND INTERNATIONAL LECTURER AND CLINICIAN, AND THE AUTHOR OF A BOOK AND DVD ENTITLED *RECOGNIZING THE HORSE IN PAIN AND WHAT YOU CAN DO ABOUT IT!*